

Analysis of Sonographic Images of Breast

M. Bastanfard, S. Jafari, and B. Jalaieian

Abstract—Ultrasound images are very useful diagnostic tool to distinguish benignant from malignant masses of the breast. However, there is a considerable overlap between benignancy and malignancy in ultrasonic images which makes it difficult to interpret. In this paper, a new noise removal algorithm was used to improve the images and classification process. The masses are classified by wavelet transform's coefficients, morphological and textural features as a novel feature set for this goal. The Bayesian estimation theory is used to classify the tissues in three classes according to their features.

Keywords—Bayesian estimation theory, breast, ultrasound, wavelet.

I. INTRODUCTION

THE intended application is the screening of young women for minimal tumors which, if detected early enough, may be removed with minimal invasion and higher probability of complete recovery; however, some of these tumors might never become cancerous; so diagnosis methods can reduce the injuries as much as possible.

In the previous works have been focused on pure textural [11] or pure morphological [3] feature set. The systems which are based on pure morphological feature set such as angular margin [9], history [14][15], shadowing area [15], bloody discharge nipple [15] and so on. These features should be considered and recognized by an expert. For these systems the highest accuracy is reported as 89.89% for malign, 91.74% for benign and 90.95% for normal tissues. The textural features such as energy, histogram, Haralick [12] and so on are used in a part of these works, which the breast's sonograms have been segmented manually [11] by an expert. The highest accuracy of these systems is reported 91.12% for malign, 92.04% for benign and 91.66% for normal tissues.

In this paper a combination of the morphological, textural and the coefficients of wavelet transform [8] as features are used to classify the sonographic images of the breast.

After the introduction wavelet transform is reviewed in section two. The preprocessing which is necessary to reduce the noise of the images is discussed in section three. The feature set in section four, classification algorithm in section five is explained and finally the experimental results are considered and compared with other well known methods.

Manuscript received March 25, 2007.

M. Bastanfard, S. Jafari, and B. Jalaieian are with Computer Science and Engineering department of Shiraz University, Shiraz, Iran (fax: +98-711-6271747; e-mail: bastanfard@cse.shirazu.ac.ir, jafaris@shirazu.ac.ir, jalaieian@cse.shirazu.ac.ir).

II. WAVELET TRANSFORM

Wavelet transforms allow a signal to be decomposed such that frequency characteristics and the location of particular features in a time series may be highlighted simultaneously. This procedure overcomes the basic shortcoming of Fourier analysis [13], where the spectrum only contains globally averaged information, which leads to location-specific features in the signal being lost. In this paper the wavelet transform as an interrogation tool for unstationary signals of ventricular fibrillation is used. The wavelet transform of a continuous time signal $x(t)$ is defined as:

$$T(a, b) = 1/\sqrt{a} \sum_t g((t-b)/a).x(t) \quad (1)$$

Where $g((t-b)/a)$ is the analyzing wavelet function. The transform coefficients $T(a, b)$ are found for both specific locations on the signal, $t=b$, and for specific wavelet periods (which are a function of a). It is usual to plot $T(a, b)$ against a and b in either a surface or contour plot, known as a scalogram. This equation is a series of convolutions in time: the original signal and wavelet function of period a .

1	2	2	
3	4		2
3	4		
		3	4

Fig. 1 Sub bands of wavelet transform in 3 levels

III. NOISE REDUCTION

With all of advantages of the sonographic images it has not been used widely in the diagnosis methods because of its awfully noises [5]; thus, an efficient noise removal is necessary before any post processing. Usually the sonograms are corrupted by speckle noise [7][2].

The speckle noise is multiplied to the image. To reduce this kind of noise and improve the quality of the image, the corrupted image should be converted to additive noise to signal. This can easily be done by using the logarithmic transform [2] as given in equation (1) and (2).

$$S(i, j) = F(i, j) \times N(i, j) + F(i, j) \quad (2)$$

$$\text{Ln}(S(i, j)) = \text{Ln}(F(i, j)) + \text{Ln}(1 + N(i, j)) \quad (3)$$

Where $S(i,j)$ is a speckled noisy image, $N(i,j)$ is the noise and $F(i,j)$ is the image without the noise.

Equation (2) indicates the original corrupted ultra sound image and equation (3) shows the natural logarithm transform of equation (2). It can be seen that the multiplicative noise with signal has been transformed to usual additive signal plus noise. This noise could be reduced appropriately using a wiener adaptive filter in the wavelet domain termed as adaptive digital image filtering method [6]. After the inverse wavelet transform, an exponential filter [2] is used to inverse the effect of the logarithm filter. Finally to enhance the contrast of the image the result of previous step should be added to itself to enhance the contrast of the image. The whole process is shown in Fig. 2.

The result of noise removal process can be seen in Fig. 3; as three samples which indicates three kinds of tissues; normal tissue, malignant tissue and benignant tissue. In addition, the Cepstrum [2] filtered image of each one is attached to compare. This shows that the adaptive digital image filtering method is so effective for ultra sound images as well as MRI images [6].

IV. FEATURE EXTRACTION

The set of features which are used in this classifier system is contained: (All the features are normalized to {0,1}).

A. Morphological Features

For minimal tumors which has no equal chance to become cancerous; the following features might be used.

- Inheritance [9]: according to whether breast cancer exists or not in a family various chances will appear. This factor would be equal to several values corresponding to:
 - 0.00: no one had breast cancer in family.
 - 0.15: one or more cases in farther family.
 - 0.60: ...one of mother or sister(s).
 - 0.85: ...both mother and sister(s).
- History : whether exists any problem or not till now.
 - 0.00: no any problem since now.
 - 0.20: one papilloma[14][15] exists in a duct.
 - 0.75: papillomatosis[14][15] in the duct(s).
 - 0.85: there exist tumor(s) which has been removed.
- Angular margin: The boundary masks which are obtained in 2.3 can be used to train a neural network (MLP) [10][4] with 2 hidden layers and back propagation algorithm to classify the Angular and Smooth margins of the masses. Wavelet transform in 3 levels is applied to the boundary mask (which is obtained by segmentation algorithm) using 'db1' as wavelet.
- Energy ratio
The ratio between energy of 4th sub band and energy of 2nd sub band also the ratio between energy of 4th sub band and energy of 3rd sub band in each level(1st, 2nd and 3rd level).
- Entropy ratio
The ratio between entropy of 4th sub band and entropy of 2nd sub band also the ratio between entropy of 4th sub band and entropy of 3rd sub band in each level(1st, 2nd and 3rd level)
- Energy of 1st sub band of level 3.
These items should be computed as features for classification.
- Shadowing: This feature shows the darkness of a mass

which is probably detected in sonogram and would be mentioned proportionally with wavelet sub bands' energy which is computed and explained in textural features.

B. Textural Features

1. Wavelet Sub Bands' Energy

Image histogram is a distribution formed by the simplest features: individual pixels which are used widely as a texture feature which can be replaced by the energy band of wavelet transform with more performance and separability for classification.

The energy of 1st, 2nd, 3rd and 4th sub bands in the 3rd level as well as energy of 2nd, 3rd and 4th sub bands in the first and second levels of wavelet transform should be computed respect to (4).

$$E = \sum_t W(t)^2 \quad (4)$$

The wavelet's coefficients have a role as shadowing which is pointed in morphological feature set.

2. Haralick Features

The Haralick features should be calculated according to gray level Co-occurrence matrix [11]. Features which are used here in this investigation are defined as:

▫ Texture Entropy

$$E = -\sum_m C_m \log C_m \quad (5)$$

▫ Texture Correlation

$$Co = \sum_j (i - \mu)(j - \mu)C / \delta^2(i)\delta^2(j) \quad (6)$$

It is obvious from the fact that it is the principal direction in the sonogram, the direction in which ultrasonic wave propagates through the tissue.

From the searched interval of 0...15, distance vector was determined as [5, 0]. This is the distance vector d that should be used to compute co occurrence matrix C for Haralick features [12].

V. CLASSIFICATION

In a classification process the goal is to assign an unknown sample to one of the categories. Here three categories are defined for classifying the breast's sonograms.

- Normal
- Benign tumors
- Malign tumors

In learning phase, the target is to build a model which generally comprises of samples with known class labels. The basic notation is the sample vector $S = \langle V, T \rangle$ which is a set of measurements $V = \{ v_1, v_2, \dots, v_n \}$ as features and T as target value.

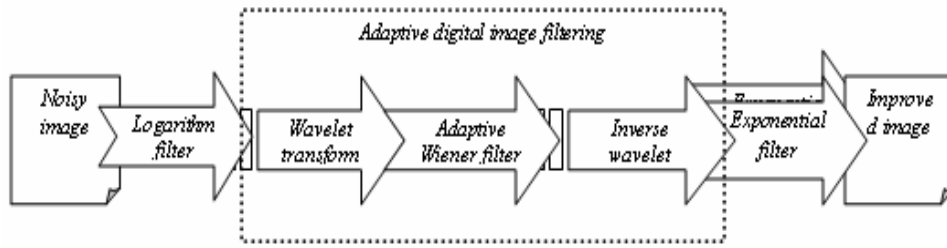


Fig. 2 Noise removal diagram

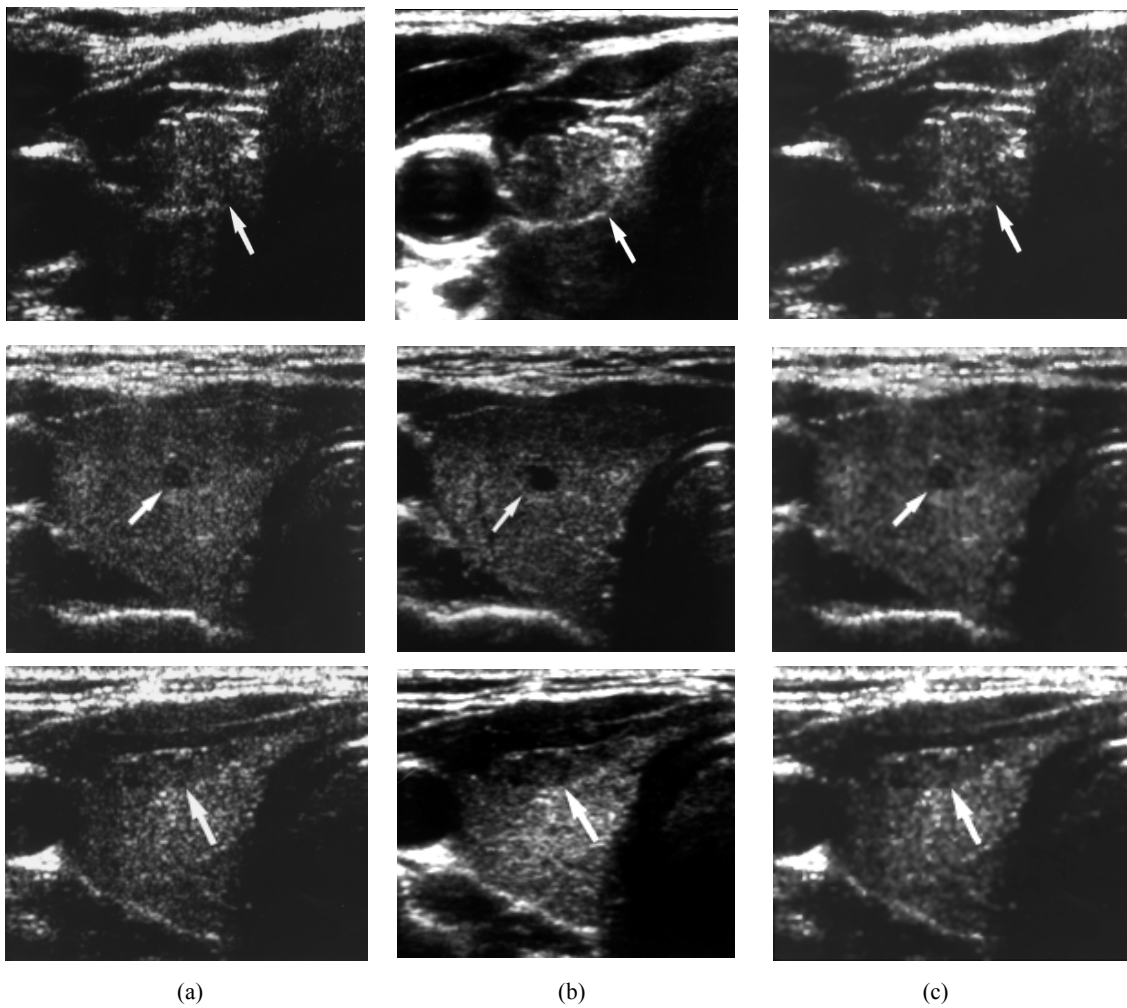


Fig. 3 Effect of filtering method
a: original breast's sonogram, b: proposed method and c: Cepstrum filter
The arrow indicates the interesting area

An unknown sample is first described with the same analysis method. The features of it are compared to those of the training samples with the classification algorithm, and the sample is assigned to the category with the highest probability (best match).

To classify the samples a parametric statistical classifier is used. Bayesian decision theory [13]:

$$P(W | X) = P(X | W)P(W) / \sum_Y P(Y | W)P(W) \quad (7)$$

Where $X = \{x_1, x_2, \dots, x_n\}$, and W_i is belong to $\{Normal, Benign, Malign\}$.

VI. EXPERIMENTAL RESULTS

A set of ultrasonic images which is contained 980 sonograms and pathologically proven benign breast tumors from 372 patients, cancerous from 343 patients and normal tissue from 265 candidates is considered.

Sonography is performed using an ATL HDI 3000 system with a L10-5 small part transducer. The data set contains only one image from each patient. The patients' ages ranged from 28 to 64 years.

From this data set 900 sonograms are used to train the system as training set and 80ones to test the classifier system. The experiment was repeated for several times and the average of the results is computed as shown in Table I.

TABLE I
THE EXPERIMENTAL RESULTS FOR ALL KINDS OF TISSUES

	Malign	Benign	Normal
Train phase	92.24%	92.81%	91.98%
Test phase	91.36%	92.10%	91.75%

VII. DISCUSSION

Results of other diagnosis classifiers which are focused purely on textural [11] or morphological [3] features are available which can be compared with our method. Table II and Fig. 4 show the performance of proposed method comparison with two other systems.

As mentioned in this paper using a useful combination of two sets of features; textural and morphological features; could improve the performance of the biomedical classifier system to reduce the injuries to a patient as much as possible.

TABLE II
THE COMPARISON BETWEEN METHODS

	Our suggestion	Textural	Morphological
Malign	91.36%	91.12%	89.89%
Benign	92.10%	92.04%	91.74%
Normal	91.75%	91.66%	90.95%

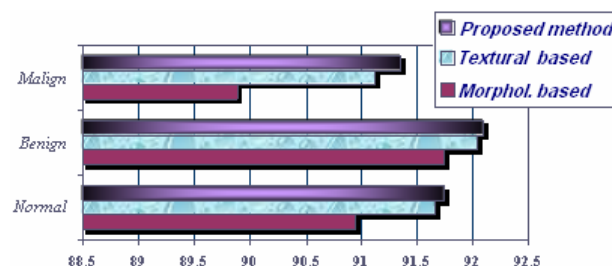


Fig. 4 Diagram of the Performance of Various Methods

REFERENCES

- [1] J. R. Sullins. Distributed learning of texture classification. In O. Faugeras, editor, First European Conference on Computer Vision, 2004.
- [2] Anil K. Jain. Fundamentals of Digital Image Processing, Prentice Hall International, Inc., 8:313-387, 1989.
- [3] B.V., Kluwer. Breast Cancer Research and Treatment, Springer Science+Business Media Academic Publishers B.V., Volume 89, Number 2, January 2005.
- [4] C. M. Bishop. Neural Networks for Pattern Recognition. Clarendon Press, 1995.
- [5] H. Gmb, European Radiology journal, Springer-Verlag, Volume 14, Number 8, August 2004.
- [6] Hassan J. Eghbali, "Adaptive digital image filtering in wavelet domain", vol.12, no 2, pp.275-290, 2003.
- [7] Kulkarni S, Muradali D, Moore L. SonoCT compound imaging; 176 [American Roentgen Ray Society 101st Annual Meeting Abstract Book suppl] AJR 2001.
- [8] Mallat, S. G. A Theory for multi resolution signal decomposition: The Wavelet representation. IEEE Transactions on Pattern Analysis and Machine Intelligence, Vol. 11, No. 7, 674-693, 1989.
- [9] Pisano ED, Braeuning MP, Burke E. Case 8. Solitary intra ductal papilloma. Radiology; 210:795-798, 1999.
- [10] Prof S K Shah, Fellow, V Gandhi, Non-member, "Image Classification Based on Textural features using Artificial Neural Network (ANN)", MS University of Baroda, 2004.
- [11] R. ˇS'ara, D. Smutek, P. Sucharda, and ˇS. Svaˇcina. Systematic construction of texture features for Hashimoto's lymphocytic thyroiditis recognition from sonographic images. In S. Quaglini, P. Barahona, and S. Andreassen, editors, Artificial Intelligence in Medicine, LNCS, Berlin-Heidelberg, Germany, 2001.
- [12] R. ˇS'ara. Sonograph images: Texture analysis [online]. C 1998, last revision 9th of November 2000. <http://cmp.felk.cvut.cz/~sara/Sono/sono.html>.
- [13] R. O. Duda and P. E. Hart. Pattern Classification and Scene Analysis. A Willey-interscience publication, 1973.
- [14] Vargas HI, Romero L, Chlebowski RT. Management of bloody nipple discharge. Curr Treat Options Oncol; 3(2):157-61, 2002.
- [15] Yeh ED, Keel SB, Slanetz PJ. Intra ductal papilloma of the breast, 2003.