

Recent Outbreaks of Highly Pathogenic Avian Influenza Virus in Chickens and Ducks in Egypt: Pathological Study

A.A Abou-Rawash, H.S. Abd EL-Hamed, H A. Abd-Ellatieff, S. M. Elsamanoudy

Abstract—Clinically, chickens showed progressively developed clinical signs represented by sever cyanosis of the comb and wattles with hemorrhage at the shanks, depression, and ruffling feathers with loss of appetite and high daily mortalities. The ducks showed severe neurological signs as torticollus, seizures and inability to stand with mild signs of diarrhea and depression. Grossly, chickens showed hemorrhages and congestion in most of the organs particularly lung, liver, spleen, trachea and kidney. The examined ducks showed multiple petechial hemorrhages, multifocal hemorrhagic necrosis in the pancreas, pulmonary edema, congestion and hemorrhage in meninges and congestion in the skeletal muscles. Histopathology revealed severe congestion and hemorrhages in most of the organs particularly lung, liver and kidney. Microscopic erosive tracheitis, sever pulmonary congestion and perivascular oedema and lympho-granulocytic pneumonia were constant. The liver showed hepatocysts necrosis and lympho-granulocytic infiltration. The kidney showed renal tubular necrosis and diffuse congestion. Multifocal, neuronal necrosis, hemorrhages, multifocal glial nodules, lympho- histiocytic perivascular cuffing, and occasional neuronophagia were observed in the cerebrum. Other organs showed moderate changes.

Keywords—Chicken, Ducks, H5N1 Avian Influenza, Pathology

I. INTRODUCTION

ON February 2006, infection with H5N1, HPAI was reported in Egypt among domestic poultry in more than 20 governorates, resulting in severe losses for the poultry industry; [1]. This sudden increase in H5N1 activity in Egypt occurred without prior identification of any deaths of wild birds in those regions. The Egyptian government initiated a poultry stamping out program and culled more than 34 million birds and implemented a poultry vaccination program. That efforts largely appeared to limit the outbreaks, however, H5N1, HPAIV is now endemic in Egypt and recurrent outbreaks among poultry are likely and the number of human H5N1 infections in Egypt is the highest of any country outside Asia. [14], [23]. During the last few years several contradictory reports have been published denoting mutation of the strains prevalent in Egypt.

A.A Abou-Rawash is with Department of pathology, Faculty of Veterinary Medicine, Damanhour University Egypt. (phone: +02-03-5274160; mobile phone: 01001176809; e-mail: Rawashaa@yahoo.com.)

H.S. Abd EL-Hamed, is with Poultry Diseases, Faculty of Veterinary Medicine, Damanhour University Egypt (e-mail: drhatem_deltavet@yahoo.co.uk).

H A. Abd-Ellatieff, is with Department of pathology, Faculty of Veterinary Medicine, Damanhour University Egypt (e-mail: dr_hodaha@yahoo.com).

S. M. Elsamanoudy, is with the National Institute of Animal Health, Alexandria Regional Laboratory, Alexandria, Egypt (e-mail: eshahenz@yahoo.com).

Reference [26] reported that HPAI specimen collected from common teal along the northern coast of Egypt appears to have harbored a strain very closely related to the parent strain responsible for the HPAI H5N1 outbreak in Egypt in February 2006 with 98% homology. In the contrary [4] reported that Phylogenetic comparison between the 2006 and 2008 Egyptian isolates of H5N1 has clearly demonstrated that emergence of significant nucleotide changes, particularly in the HA domains, might result in changes in the antigenicity of isolates. Again, great genetic differences and variations between the isolate of 2007 (clade 2.2) and the isolates of 2010 (clade 2.2.1) were reported, and it has been concluded that H5N1 is continuing to mutate with multiple heterogenic strains persisting in Egypt [3]. The relationships between these mutation and pathogenesis have not been clarified. These reports motivated us to investigate histopathological changes of the most recent natural outbreaks of avian influenza in commercial and house reared poultry flocks as well as phylogenetic analysis of the isolated viruses. If your paper is intended for a *conference*, please contact your conference editor concerning acceptable word processor formats for your particular conference.

II. MATERIAL AND METHOD

All AI samples were collected between January 2009 and April 2011.

A. Chickens

A total number of 30 dead and diseased broiler chicken were collected from six diseased flocks, 5 case each, in addition to 25 samples collected from 5 backyards flocks from different villages in Damanhour governorate .

B. Ducks

A total number of 10 dead and apparently diseased ducks were collected from 5 diseased backyards flocks that were reared with the same infected backyards chickens flocks located in different villages in Behera governorate.

Dead and diseased chickens and ducks were necropsied. At necropsy a set of tissue specimens were collected from liver, lung, kidney, spleen, trachea and brain and immediately fixed in formol buffered saline 10% until used for histopathological examination. Another set of tissue specimens were aseptically collected from lungs and trachea for detection and identification of virus by immunochromatography, Hemagglutination (HA), Hemagglutination Inhibition (HI) and Real-time Polymerase chain reaction (RT-PCR).

C. Virus isolation and Identification

1. Sample Preparation

At necropsy, specimens from lungs and tracheae were collected from chicken and ducks naturally infected with HPAI H5N1 in Egypt between 2009 and 2011. The samples were separately homogenized in phosphate-buffered saline containing mixture of antibiotics and stored at -70°C till virus isolation was attempted.

2. Virus Isolation And Identification

For virus isolation, 11 day old specific pathogen-free Embryonated Chicken Eggs (ECE) were inoculated with the prepared tissue samples.

Detection of type A H5N1 avian influenza virus were carried out by Immunochromatography (IC kit, Animal Genetics, Inc.) by using newly established monoclonal antibodies according to [30], Hemagglutination (HA) and hemagglutination inhibition (HI) according to OIE Manual [23], and RT-PCR according to [16].

D. Post mortem And Histopathological Examination

Post mortem examination was performed on freshly dead and sacrificed birds. Tissue specimens of trachea, lungs, liver, pancreas, spleen, intestine, kidneys, brain, combs and muscles were collected from all dead and euthanized birds. The specimens were properly fixed in 10 % neutral buffered formalin, routinely paraffin processed and H&E stained according to [5].

III. RESULTS

A. Clinical Signs In Chickens

The clinical signs observed of the infected birds began with depression, ruffling feathers and loss of appetite, then followed by hemorrhage at the shanks with severe cyanosis and edema of the comb and wattles in most of them, some times included the whole head. few chicken showed nervous signs. The affected birds then become recumbent unable to move and succumb.

Clinical signs in ducks: Regarding the naturally infected ducks, the most common signs were sinusitis, diarrhea and an increased mortality rate. Furthermore there were severe nervous signs as drowsiness, ataxia, torticollis, circling, severe weakness and incoordination, inability to stand, seizures, with blindness, and greenish diarrhea, cloudy eyes, and ruffled feathers.

B. Gross Pathology

The mainly observed lesions characterized by hemorrhage and congestion of the internal organs. The skin and subcutaneous tissue showed focal congestion, trachea is focally hemorrhagic, lung showed severe congestion, brain is congested with enlargement of the kidney lobule and congestion. While in naturally infected ducks, the most consistent lesions were multiple petechial hemorrhages, multifocal hemorrhagic necrosis in the pancreas, pulmonary

edema and congestion in the skeletal muscles. The brain showed congestion and hemorrhage in meninges.

C. Histopathological Findings

1. Chickens

Trachea showed multifocal desquamation of the epithelial lining the non desquamated cells showed multifocal deciliation (Fig.1). The lamina propria exhibited severe multifocal lymphocytic tracheitis with congestion of blood capillaries and interstitial edema.

The lung of all birds showed severe acute diffuse exudative interstitial pneumonia with heterophilic and mononuclear leukocytic cells infiltration. The bronchial mucosa had erosions and extensive inflammatory cells infiltrations in the underlying lamina propria with severe congestion of the blood vessels and severe edema around blood vessels and lung lobules (Fig. 2, 3). The adventitia of the pulmonary blood vessels showed severe edema with swelling and vacuolization of the lining epithelium. Focal hemorrhages with numerous inflammatory cells were noticed in the lung lobules. Occasional necrosis of air capillary endothelium was also present.

Liver lesions were constantly found in all examined cases and varied only in severity. congestion of the sinusoids is with multifocal hemorrhage were marked and constant the hepatocytes showed necrotic changes varied from vacuolar degeneration to massive multifocal lytic necrosis with heterophilic and mononuclear interstitial hepatitis and showing congestion, vasculitis, and perivascular lymphocytic infiltration. The portal areas showed irregular lymphohistiocytic inflammatory cells infiltrations (Fig. 4, 5).

The renal lesions of the most of the chicken were constant findings. The kidney had severe, diffuse renal tubule necrosis and moderate, multifocal heterophilic and lymphocytic tubulointerstitial nephritis. Tubular atrophy was sometimes detected. The renal glomeruli showed hypercellularity and congestion of the capillaries and close positioning (Fig.6, 7).

Brain: Histopathology. Diffuse lesions were present mainly in the cerebral gray matter and brain stem. There was moderate multifocal lymphocytic meningoencephalitis. In the cerebrum, multifocal, moderate to severe necrosis of neurons and glial cells and hemorrhages were found. Corresponding to these lesions, prominent multifocal glial nodules and occasional neuronophagia (Fig. 8) could be observed in the cerebral gray and white matter. The blood vessels showed multifocal perivascular cuffing with lymphocytes, purkinje cell layer degeneration (Fig. 9), fewer histiocytes, and small numbers of heterophils. additional extensive, multifocal to coalescent, irregularly shaped, moderately demarcated areas of liquefactive necrosis were found in the cerebrum, characterized by central complete loss of neuropil, leaving small amounts of pale eosinophilic material, and few finely vacuolated macrophages (gitter cells).

Spleen: the spleen had hyperplasia of phagocytic cells and many of them were vacuolated as well as severe congestion of

the red pulp with necrobiosis and depletion of lymphocytes in the lymphoid follicles.

Pancreas: There were hyperplasia of the excretory duct with congestion and focal necrosis of the pancreatic acini (Fig. 10).

Heart: thickening of the pericardium with severe congestion and multifocal myocardial degeneration and lympho-histocytic inflammatory cell infiltration in-between the cardiac muscles bundles (Fig.11).

Small intestine: there were hemorrhages in the tips of villi. Enteritis with sloughing of the epithelial lining intestinal villi and focal mononuclear cell infiltrations were also detected .

Proventriculus: there were severe congested blood vessels with aggregates of inflammatory cells infiltration in the lamina propria .

Gizzard: focal sloughing of epithelial mucosa with congested blood vessels and leukocyte cell infiltration between muscles especially lymphocyte.

Comb and Wattles: marked edema and congestion and hemorrhage were prominent. Heterophils were aggregated within congested blood vessels and infiltrating the edematous loose subcutaneous tissue were also prominent (Fig. 12).

2. Ducks

Lung: The lung showed variable lesions from congestion and interstitial edema to marked lymphocytic pneumonia with hemorrhage affecting the whole lobule. In some dead case, the lumens of primary bronchioles were filled with exudates, with desquamation of the bronchial mucosa and extensive inflammatory cells infiltrations in the underlying lamina propria and the surrounding air capillaries and interstitium, with severe congestion of the blood vessels, marked perivascular and interstitial edema were also present (Fig.13).

Trachea: The trachea showed multifocal desquamation of the epithelial lining, the non desquamated cells showed multifocal deciliation. The lamina propria exhibited moderate multifocal lymphocytic tracheitis with congestion of blood vessels (figs. 14).

Liver: The liver showed variable changes represented by mild congestion in some cases, with focal vacuolation of hepatocytes. There were mild focal necrosis of hepatocytes with mild increase in sinusoidal cellularity attributed to the combined presence of Kupffer cell hyperplasia, and increased numbers of mononuclear cells in the portal triads of liver, with severe distribution of fatty change within the hepatocytes (Fig.15).

Kidney: Mild to moderate congestion, with mild degeneration of renal tubules, and discrete foci of tubular epithelial necrosis were found in the kidney. Non suppurative interstitial nephritis with regenerating renal tubules with inflammatory cells infiltration were also noted.

Brain: Severe congestion of blood vessels with vacuolation, gliosis and neuronophagia and variable degree of encephalomalacia . The blood vessels showed multifocal perivascular cuffing with lymphocytes, purkinje cell layer degeneration, severe neuronal degeneration with

encephalomalacia in the cerebrum (Figs.16-18).

Spleen: Severe congestion with mild lymphocytic depletion and necrosis of peri-arteriolar sheaths and lymphoid follicles were present in the spleen.

Pancreas: Although variable, pancreatic lesions were constant findings. It showed multifocal areas of acinar necrosis, congestion and hemorrhages with perivascular edema and hyperplasia of pancreatic duct. In severely affected cases, endocrine areas and a surrounding zone of normal exocrine tissue remained as islands in the otherwise diffusely necrosed, inflamed and hemorrhagic pancreatic tissue (Fig. 19, 20).

Heart: Multifocal hemorrhage and mild degeneration of the myocardium, and lympho-histocytic inflammatory cells infiltration in-between the cardiac muscles bundles were often detected (Fig. 21).

Small intestine: Mild to moderate mucosal necrosis, sloughing of the epithelial lining intestinal villi, fusion of the villi tips and focal mononuclear and heterophilic cell infiltrations in the lamina propria were all detected in duodenum.

IV. DISCUSSION

Natural infection of chickens and ducks in the present study was rapidly diagnosed by immunochromatography and RT-PCR. The sub-typing of the infective virus was confirmed by HA and HI using monospecific antisera against H5 and N7 subtypes antigens. The reliability of rapid diagnosis of type A AI was proved [16], [33]. Sensitivity and specificity of the RT-PCR compared with Virus isolation, (VI) were 95.4% and 86.6%, respectively. [19]. Reference [8] compared RT-PCR and Directigen ® diagnostic kit with VI on specimens collected from experimentally infected birds and indicated a good correlation between the results of the three tests.

The present study clearly proved that farmed broiler chickens was as susceptible to the circulating clade / clades of H5N1 HPAIV as the non vaccinated backyards reared chicken and ducks, in Behera governorate, Egypt. These naturally infected chicken exhibited acute fatal disease characterized by clinical signs in complete agreement with the former results of HPAI virus formerly isolated [12], [22]. Occurrences of the disease in farmed chicken could be attributed to vaccination strategy failure as have been reached by [4].

The clinical signs in the affected chickens were depression with cyanosis of the comb and wattles, facial edema and hemorrhages on shanks and feet with high mortality sometimes reached to 100%. These findings were gone parallel with those observed by [20]. On post mortem examination, severe hemorrhages at multiple organs were frequent in chickens infected with highly pathogenic avian influenza, (H5N1) viruses as previously observed [21].

In a former studies on chicken and turkeys, macroscopic and microscopic lesions caused by HPAI infections were dominated by acute hemorrhages, oedema and necrosis (e.g. oedema in the skin of the head, neck and legs, and in lungs; hemorrhages in the skin, under serous membranes, in the

mucosa, and pectoral muscles; necrosis in the skin, pancreas, spleen and heart [1], [2], [17], [28].

Focal hemorrhages, perivascular edema, severe congestion of myocardial blood vessels with necrotic damage of the vascular wall, with degeneration of myocardial bundles and inflammatory cells infiltration were recorded in infected chickens. These findings were in agreement with former reports [15]; They also suggested that HPAIV had strong tropism for the cardiovascular system principally vascular endothelium. These well-developed lesions in the heart and together with the lesions reported in cardiovascular system and/or, brain, could be responsible singularly or collectively for illness and death of the affected birds as have been reached by [27].

In the present study, microscopic examination of the kidney revealed focal hemorrhage, congestion, with degeneration and necrosis of renal tubules and interstitial infiltration with mononuclear leucocytes; which apparently disagree with some earlier reports of AI infection [1], [16]. They reported that; with HP AIVs, kidney lesions were a minor or absent feature. On the other hand [23] stated that, the kidney was a significant site of lesion production and AI virus replication. In our opinion, a portion of this variation may be attributed to differences in host age, route of inoculation, and virus inoculum dose. However, in some other studies [32] reported that, the lack of kidney lesions in dead birds were attributed to early and rapid virus replication, injury, and death to significant cell populations in critical organs, such as heart, brain, or capillary beds. This would result in peracute death before pathobiological and clinical manifestations of kidney tropism and pathogenicity could occur. Moreover, extensive damage to kidneys could result in clinical illness and death if the majority of kidney is acutely involved, but the pathogenesis requires a sufficiently long survival period to produce acute to subacute renal failure and death.

On the other hand, [24] reported that virulent forms of HPAI (H5N1) were characterized by a highly fatal systemic infection that spreads to most organ systems including the cardiovascular and nervous systems. Again, [20] mentioned that the most consistent and severely affected organ by this virus were lung, kidney and brain, severity of the lesions in each organ was probably related to tissue tropism. Moreover, [25] indicated that gallinaceous species were highly susceptible to infection and the pathogenesis of HPAI (H5N1) viral infection in these species relates to a combination of factors, including cardiovascular dysfunction caused by endothelial activation and disruption, leukocyte activation, and systemic cytokine release; cardiopulmonary failure; and/or multiorgan failure.

Severe congestion of the myocardial blood vessels, edema with focal extravasations of the blood cells, inflammatory cells infiltration and degeneration in the myocardium bundles were recorded in chickens could be related to strong tropism of HPAIV for vascular endothelium of the cardiovascular system [15].

In the present study Avian influenza viruses was highly pathogenic in chickens and also cause clinical disease and death in ducks, as ducks showed hemorrhage in the brain with vacuolation and congestion of the blood vessels and that is not parallel with [27]. as they mentioned that the highly pathogenic avian influenza virus is more pathogenic in chickens and did not cause clinical disease or death in ducks or wild aquatic bird. However, the histopathological findings in ducks were multifocal, moderate-to-severe necrosis of the neurons and glial cells and occasional neuronophagia with multifocal lymphocytic perivascular cuffing were observed in cerebral gray matter of infected ducks [31].

Severe inflammatory cells infiltration, congested blood vessels and ulceration of the mucosal epithelium of the trachea, massive inflammatory cells infiltration in lung, edema in the adventitia, and vacuolated swelling of the lining endothelium of the pulmonary blood vessel were all detected in ducks. The shortly mentioned findings are in contrary with [22], they recorded no lesion in the trachea or in the air capillary and blood capillary of the lung. Moreover, Most studies ducks' resistance to infection with influenza virus was emphasized after experimental infection with H5N1 influenza virus [9]. On the other hand neurological signs with blindness and mortality are in agreement with [7], [11] during outbreaks of HPAI viruses infection.

V. CONCLUSION

We could finally conclude that, Occurrence of the disease in farmed vaccinated chickens indicate without doubt failure of vaccinations strategy, or failing of vaccination procedure adopted by agriculture authorities, and both should be reconsidered as have been previously reported. Based upon the results of the present investigation, we could conclude that, the pathological and immunohistochemical changes observed in this study were similar to those described in similar and other bird species infected with HPAI virus. In addition; Absence of Fibrinopurulent inflammation of the upper respiratory tract, sinuses, air sacs or reproductive organs that are typical for infections by avian influenza strains of low pathogenicity, indicate that AI virus strains now circulating among birds in Egypt are highly pathogenic and the results of experimental work in the present investigation tell us that, the mutations that do occurred to the virus in the last years as reported by [3], [10] did not reduced its virulence, pathogenicity or the pathological picture of the virus in the affected bird species.

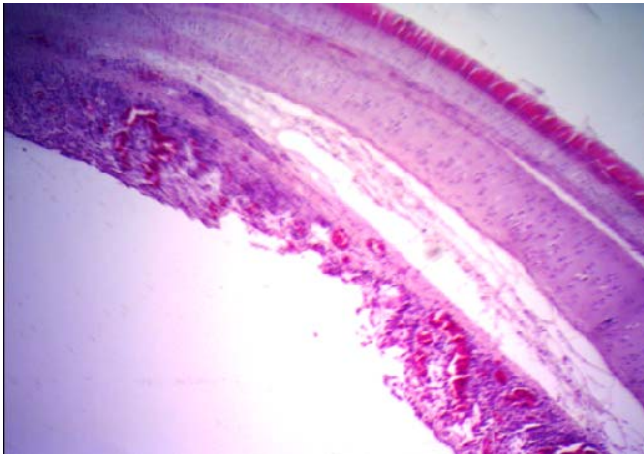


Fig. 1 Trachea showing desquamation of the epithelium, multifocal lymphocytic infiltration of lamina propria, edema and congestion (H&E X100)

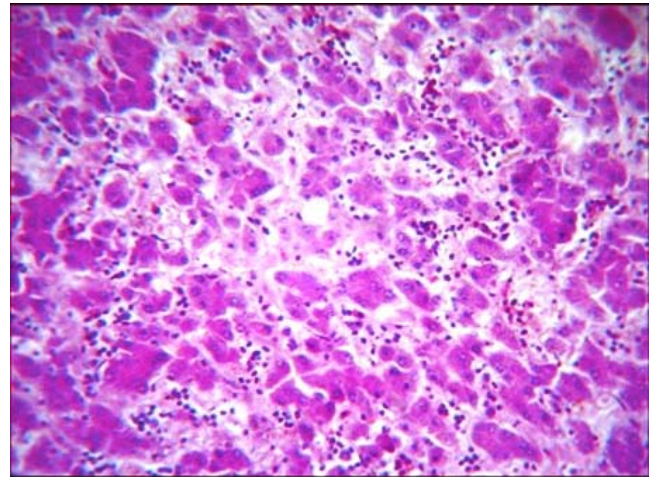


Fig. 4 showing severe necrosis of the hepatocytes (H&E X400)

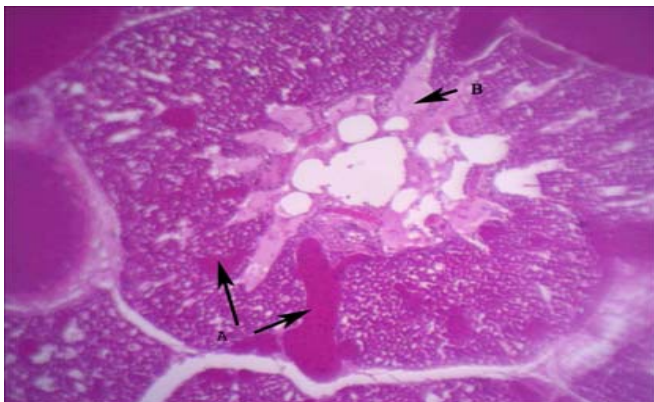


Fig. 2 lung of chicken showing severe congestion, perivascular edema, focal hemorrhage, and numerous inflammatory cells (H&E X40)

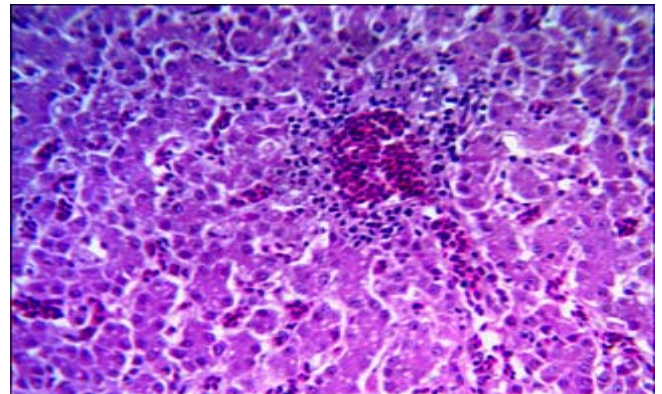


Fig. 5 liver of chicken showing congestion, vasculitis, and perivascular lymphocytic infiltration 1 (H&E X400)

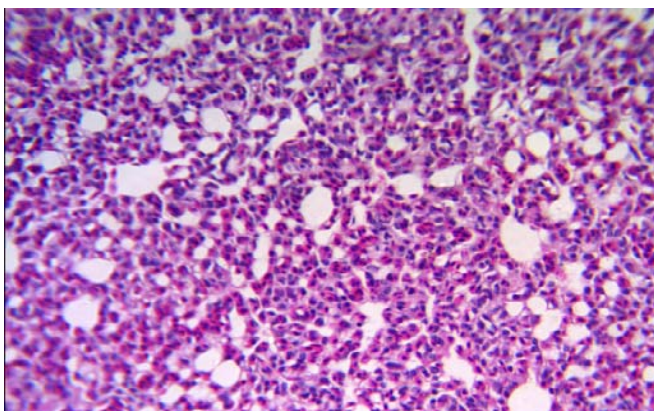


Fig. 3 Lung of a chicken showing interstitial pneumonia with heterolymphocytic infiltrations (H&E X400)

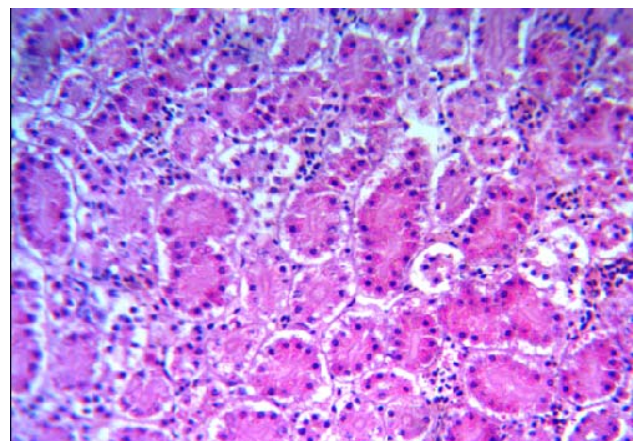


Fig. 6 Kidney of a chicken showing degeneration and necrosis of renal tubules with acute tubulo-interstitial nephritis (H&EX400)

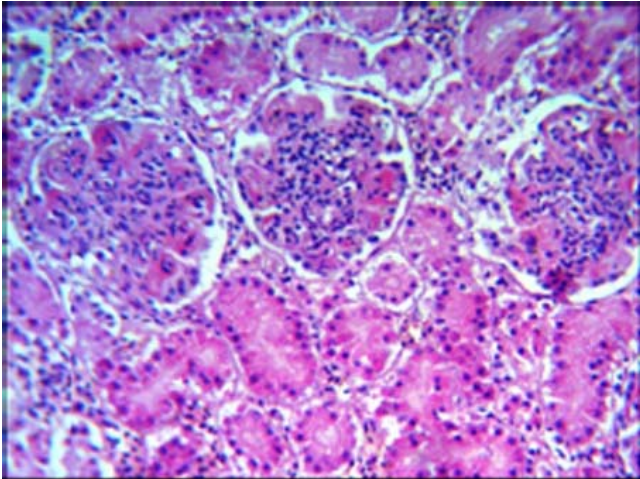


Fig. 7 Kidney showing hypercellularity and close positioning of the glomeruli with degeneration of renal tubules (H&E X400)

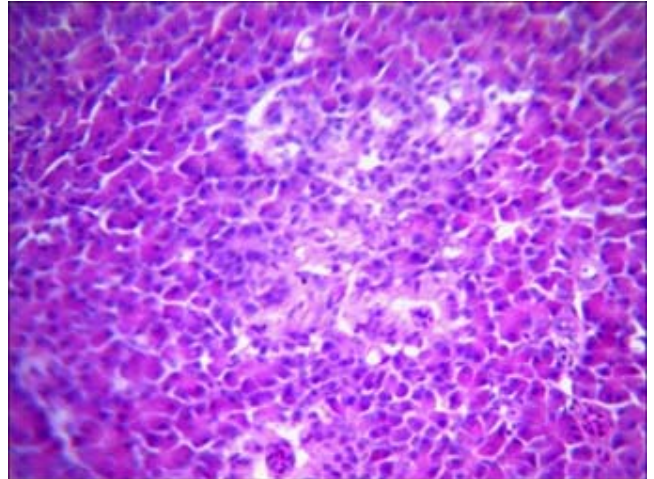


Fig 10 Pancreas showing focal necrosis of the pancreatic acini(H&E X400)

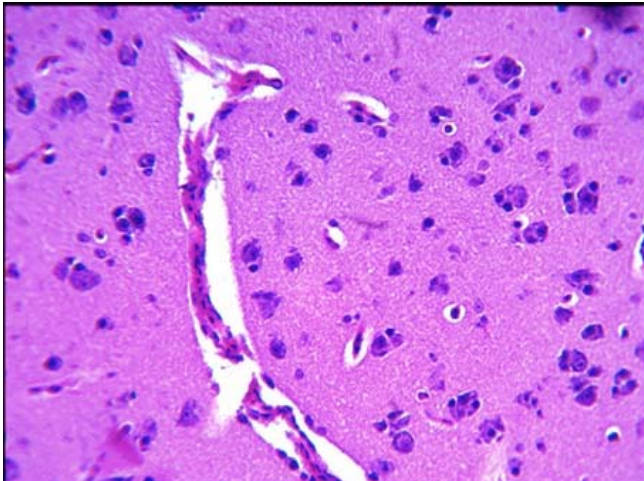


Fig. 8 Brain of chicken showing multifocal gliosis and neuronophagia (H&E X400)

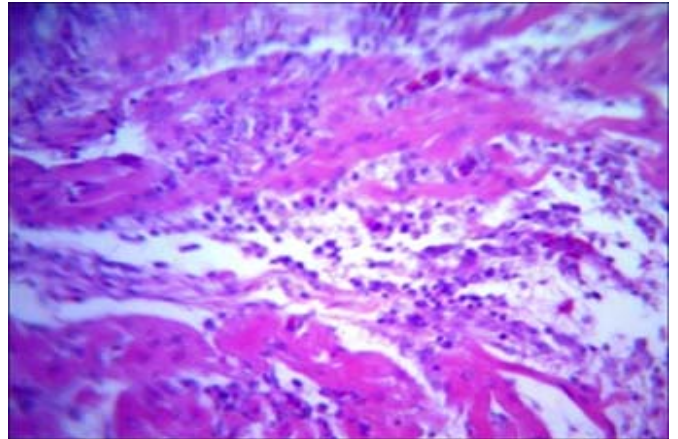


Fig. 11 Heart of chicken showing multifocal degeneration of the myocardium and lympho-histocytic inflammatory cell infiltration in-between the cardiac muscles bundles (H&E X400).

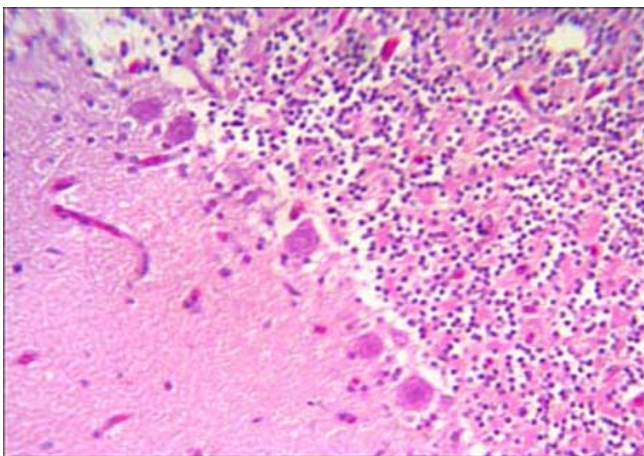


Fig. 9 Brain of a chicken showing Purkinje cell layer degeneration (H&E X400)

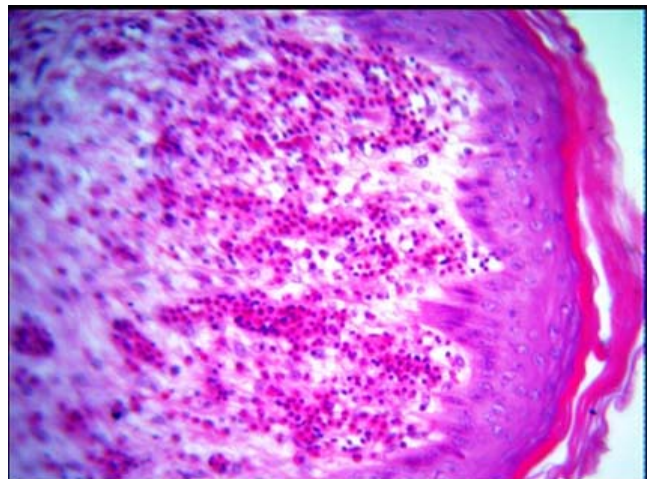


Fig. 12 Comb and Wattles showing marked edema, congestion hemorrhages, and perivascular heterophilic infiltration (H&E X400).

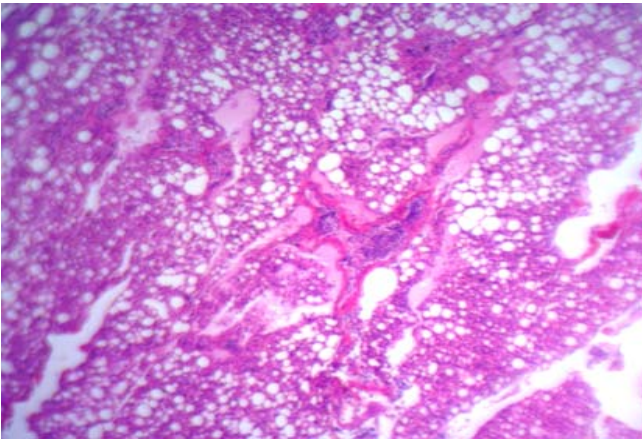


Fig. 13 Lung of a duck showing lymphocytic pneumonia with congestion of the blood vessels and perivascular edema (H&E X100)

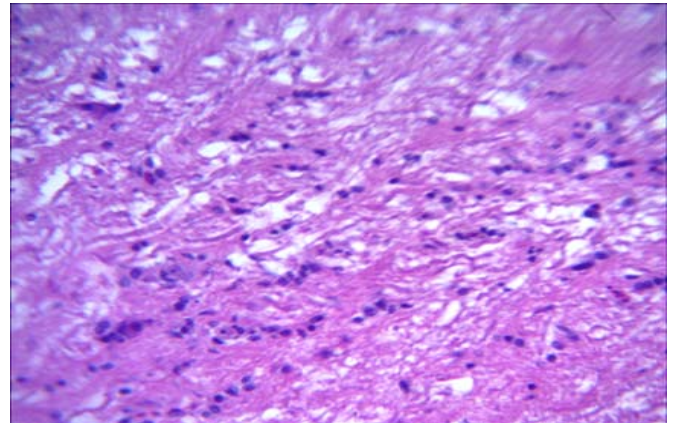


Fig. 16 Brain of a duck showing demyelination and mild gliosis of the cerebral white matter (H&E X400)

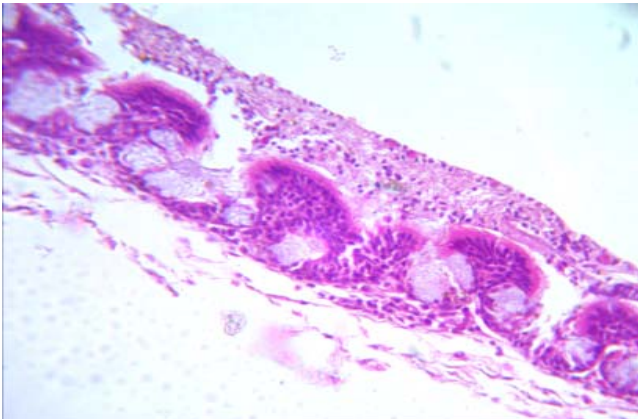


Fig. 14 Trachea of a duck showing catarrhal tracheitis, notice submucosal edema and mild leukocytic infiltrations (H&E X400)

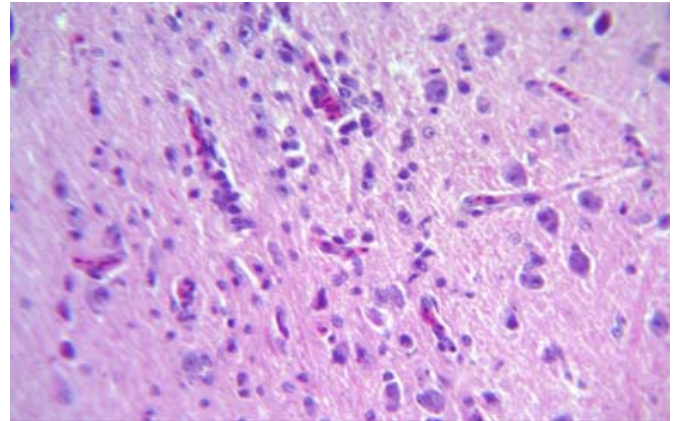


Fig. 17 Brain of a duck showing neuronal degeneration focal gliosis and perivascular cuffing in cerebrum (H&E X400)

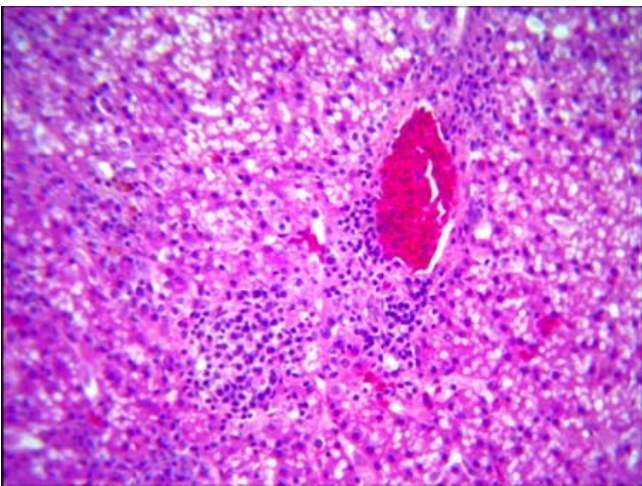


Fig. 15 Liver of a duck showing marked fatty vacuolization with perivascular leukocytic cell infiltrations (H&E X400)

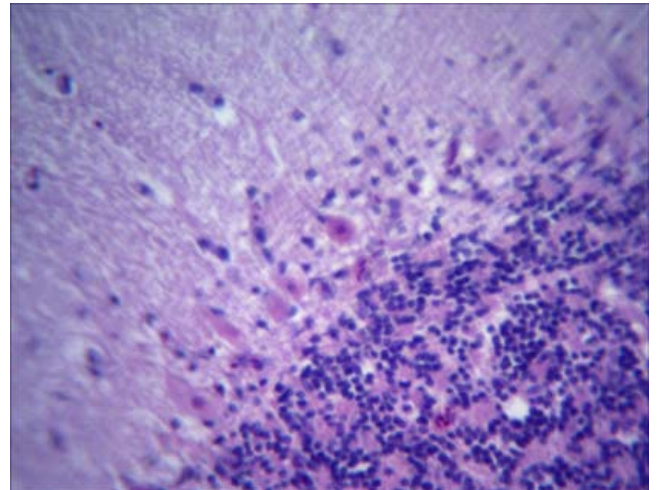


Fig. 18 Brain of a duck showing Purkinje cell layer degeneration (H&E X400)

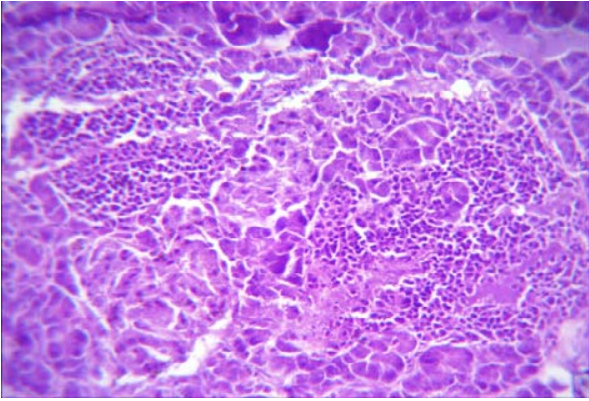


Fig. 19 Pancreas of a duck showing severe necrosis of pancreatic acini with severe heterophilic and mononuclear cell infiltration (H&E X400)

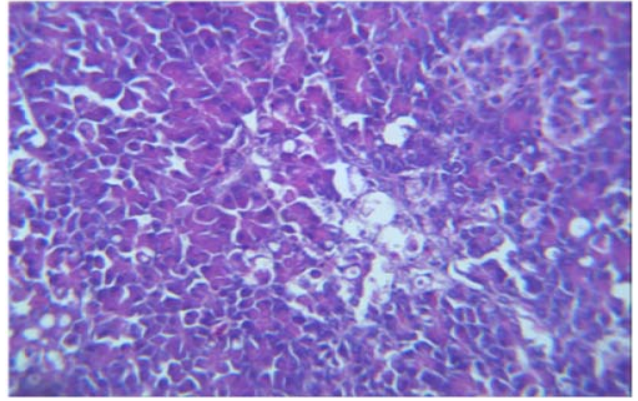


Fig. 20 Pancreas of duck showing focal necrosis of pancreatic acini (H&E X400)

REFERENCES

- [1] H. M. Acland, L. A. Silverman Bachin, and R. J. Eckroade, "Lesions in broiler and layer chickens in an outbreak of highly pathogenic avian influenza virus infection," *Vet. Pathol.*, vol. 21, pp. 564-569, 1984.
- [2] D. J. Alexander, "Avian influenza, Recent Developments," *Vet. Bul.*, vol. 52, pp. 341-359, 1982.
- [3] A. Arafa, D. L. Suarez, M. K. Hassan, and M. M. Aly, "Phylogenetic analysis of hemagglutinin and neuraminidase genes of highly pathogenic avian influenza H5N1 Egyptian strains isolated from 2006 to 2008 indicates heterogeneity with multiple distinct sublineages," *Avian Dis.*, vol. 54, pp. 345-349, 2010.
- [4] J. D. Bancroft, A. Stevens, and D. R. Turner, "Theory and practice of histopathological Techniques," 4th ed. Churchill Livingstone, New York, London, and Madrid, 1996.
- [5] M. M. Bahgat, M. A. Kutkat, M. H. Nasraa, A. Mostafa, R. Webby, I. M. Bahgat, and M. A. A. Ali, "Characterization of an avian influenza virus H5N1 Egyptian isolate," *J. Virol. Methods*, vol. 159, pp. 244-250, 2009.
- [6] C. C. Brown, H. J. Olander, and D. A. Senne, "A pathogenesis study of highly pathogenic avian influenza virus H5N2 in chickens, using immunohistochemistry," *J. Comp. Pathol.*, vol. 107, pp. 341-348, 1992.
- [7] I. Capua, and F. Mutinelli, "Mortality in Muscovy ducks (*Cairina moschata*) and domestic geese (*Anser anser* var. *domestica*) associated with natural infection with a highly pathogenic avian influenza virus of H7N1 subtype," *Avian Pathol.* Vol. 30, pp. 179-183, 2001.
- [8] G. Cattoli, A. Drago, S. Maniero, A. Toffan, E. Bertoli, S. Fassina, C. Terregino, C. Robbi, G. Vicenzoni, and I. Cappua, "Comparison of three rapid detection systems for type A Influenza virus on tracheal swabs of experimentally and naturally infected birds," *Avian Pathol.*, vol. 33, pp. 432-437, 2004.
- [9] H. Chen, G. Deng, Z. Li, G. Tian, Y. Li, P. Jiao, L. Zhang, Z. Liu, R.G. Webster, and K. Yu, "The evolution of H5N1 influenza viruses in ducks in southern China," *Proc. Natl. Acad. Sci. USA*, vol. 101, pp. 10452-10457, 2004.
- [10] E. M. El-gendy, "Detection and genetic characterization of avian influenza virus in some Egyptian governorate," *M.V.Sc. Thesis, Fac. Vet. Med., Alex. Univ.*, 2010.
- [11] T. M. Ellis, B. Bousfield, L. Bisset, K. Dyrting, G. S. M. Luk, S. T. Tsim, K. Sturm-Ramirez, R. G. Webster, Y. Guan, and M. J. S Peiris, "Investigation of outbreaks of highly pathogenic H5N1 avian influenza in waterfowl and wild birds in Hong Kong in late 2002," *Avian Pathol.* Vol. 33, pp. 492-505, 2004.
- [12] T. Horimoto, and Y. Kawaoka, "Pandemic threat posed by avian influenza A viruses," *Clin. Microbiol. Rev.*, vol. 14, pp. 129-149, 2001.
- [13] *International federation of Red Cross and Red Crescent societies* Egypt "Avian influenza," MDREG002, 2006.
- [14] P. Joan, P. Amisha, C. Bradley, C. Michael, O. C. Stephen, H. H. Davidson, and C. J. Elaine, "2007 year in review: avian influenza and pandemic planning," *IJET/ SR*, pp. 251-01, 2008.
- [15] Y. L. Jones, and D. E. Swayne, "Comparative pathology of low and high pathogenicity H7N3 Chilean avian influenza viruses in chickens," *Avian Diseases*, vol. 48, no. 1, pp. 119-28, 2004.
- [16] C. Kawakami, H. Shimizu, and S. Watanabe, et al. "Evaluation of immunochromatography method for rapid detection of influenza A and B viruses," *Kansenshogaku Zasshi*, vol. 75, pp.792-799, 2001.
- [17] Y. Kobayashi, T. Horimoto, Y. Kawaoka, D. J. Alexander, and C. Itakura, "Pathological studies of chickens experimentally infected with two highly pathogenic avian influenza viruses," *Avian Pathol.* Vol. 25, pp. 285-304, 1996.
- [18] M. S. Lee, P. C. Chang, J. H. Shien, M. C. Cheng, and H. K. Shieh, "Identification and subtyping of avian influenza viruses by reverse transcription-PCR," *J. Virol. Meth.*, vol. 97, pp. 13-22, 2001..
- [19] C. Magnard, M. Valette, M. Aymard, and B. Lina, "Comparison of two nested PCR, cell culture and antigen detection for the diagnosis of upper respiratory tract infections due to Influenza viruses," *J. Med. Virol.* Vol. 59, pp. 215-220, 1999.
- [20] M. J. Mehrabanpour, H. Dadras, A. Khodakaram Tafti, A. Rahimian, and A. Toffan, "Pathological findings of highly pathogenic avian influenza VirusA/Duck /Vietnam/12/2005 (H5N1) in turkeys," *Int. J. Poultry Sci.*, vol. 6, pp. 679-683, 2007.
- [21] Y. Muramoto, H. Ozaki, A. Takada, H. Park-Chun, Y. Sunden, T. Umemura, Y. Kawaoka, H. Matsuda, and H. Kida, "Highly pathogenic H5N1 influenza virus causes coagulopathy in chickens," *Microbiol. and immunol.*, vol. 50, no. 1, pp. 73-81, 2006.
- [22] H. Nakatani, K. Nakamura, Y. Yamamoto, M. Yamada, and Y. Yamamoto, "Epidemiology, pathology, and immunohistochemistry of layer hens naturally affected with H5N1 highly pathogenic avian influenza in Japan," *Avian Dis.*, vol. 49, pp. 436-441, 2005.
- [23] Office International des Epizooties (OIE) Standard Commission, "Manual of diagnostic tests and vaccines for terrestrial animals," 5th ed., OIE Publication, Chapter 2, 1-14, 2004.
- [24] D. R. Perez, S. H. Nazarian, G. McFadden, and M. S. Gilmore, "Miscellaneous threats: Highly pathogenic avian influenza, and novel bioengineered organisms," in *Biodefense: Principles and Pathogens*, M. S. Bronze, and R. A. Greenfield, ed., 2005, Horizon Bioscience, Norfolk, England.
- [25] L. E. Perkins, and D. E. Swayne, "Pathobiology of A/chicken/hong Kong/220/97(h5n1) avian influenza virus in seven gallinaceous species," *Vet. Pathol.*, Vol. 38, pp. 149-164, 2001.
- [26] M.D. Saad, M.A. Gammal-Eldein, L.S. Ahmed, A.S.A. Goda, M.S. Khalil, M.A. Fouda, S.L. Yingst, M.A. Parker, and M.R. Monteville, "First record of Avian Influenza (H5N1) in migratory birds in Egypt," *SCVMJ*, vol. 8, no. 1 pp. 93-104, 2008.
- [27] D. E. Swayne, "Understanding the complex pathobiology of high pathogenicity avian influenza viruses in birds," *Avian Diseases*, vol. 50, pp. 242-249, 2007.
- [28] D. E. Swayne, and D. Suarez, "Highly pathogenic avian influenza," Office International des Epizooties press, *Scientific and Technical Review*, vol. 19, pp. 463-482. (2000):
- [29] D. E. Swayne, M. J. Radin, T. M. Hoepf, and R. D. Slemmons, "Acute renal failure as the cause of death in chickens following intravenous inoculation with avian influenza virus Al thicken/Alabama/7395/75 (H4N8)," *Avian Dis.*, vol. 38, pp. 151- 157, 1994.
- [30] Y. Tsuda,, Y. Sakoda, S. Sakabe,, T. Mochizuki,, Y. Namba, and H. Kida, "Development of an immunochromatographic kit for rapid diagnosis of H5 avian influenza virus infection," *Microbiol. and Immunol.*, vol. 51, pp. 903-907, 2007.
- [31] M. Vascellari, A. Granato, L. Trevisan, L. Basilicata, A. Toffan, A. Milani, and F. Mutinelli, "Pathologic Findings of Highly Pathogenic Avian Influenza Virus A/Duck/Vietnam/12/05 (H5N1) in Experimentally Infected Pekin Ducks, Based on Immunohistochemistry and In Situ Hybridization," *Vet. Pathol.*, vol. 44, pp. 635-642, 2007.
- [32] G. W. WOOD, G. Parsons, and D. J. Alexander, "Replication of influenza A viruses of high and low pathogenicity for chickens at different sites in chickens and ducks following intranasal Inoculation. Short communication," *Avian Pathol.*, vol. 24, pp. 545-551, 1995.
- [33] M. Yamazaki, K. Mitamura, and K. Kimura, et al, "Clinical evaluation of an immunochromatography test for rapid diagnosis of influenza," *Kansenshogaku Zasshi*, vol. 75, pp. 1047-1053, 2001.