

# Segmentation of Ascending and Descending Aorta in CTA Images

H. Özkan

**Abstract**—In this study, a new and fast algorithm for Ascending Aorta (AscA) and Descending Aorta (DesA) segmentation is presented using Computed Tomography Angiography images. This process is quite important especially at the detection of aortic plaques, aneurysms, calcification or stenosis. The applied method has been carried out at four steps. At first step, lung segmentation is achieved. At the second one, Mediastinum Region (MR) is detected to use in the segmentation. At the third one, images have been applied optimal threshold and components which are outside of the MR were removed. Lastly, identifying and segmentation of AscA and DesA have been carried out. The performance of the applied method is found quite well for radiologists and it gives enough results to the surgeries medically.

**Keywords**—Ascending aorta (AscA), Descending aorta (DesA), Computed tomography angiography (CTA), Computer aided detection (CAD), Segmentation

## I. INTRODUCTION

THORACIC computed tomography angiography scans provide information about cardiovascular risk status. Computer Aided Diagnosis schemes for thoracic CTA are widely used to detect numerous abnormalities. Image segmentation is widely used to characterize, quantify, and detect numerous aorta abnormalities, such as plaques, aneurysms, calcification, or stenosis. Therefore, segmentation of the coronary arteries in pulmonary CTA images is a challenging research area for several research groups. Some of the applied methods are border estimation [1-5], neural network [6], watershed-based [7], region growing [8-11], level set-based [12], fast marching [13], model-based segmentation [14], and Hough Transform [15]. Most of them still need a manual initialization in form of seed points in the origins of the coronary arteries. Most of the automatic segmentation of the ascending aorta can close the gap towards a fully automatic segmentation of the coronary arteries which is very useful and important for the diagnosis of coronary heart diseases. In this paper, a new CAD system for automatic segmentation of AscA and DesA are improved in CTA images. AscA and DesA segmentation is differently carried out from previous works. Lung segmentation and detection of MR are necessary processes that can be used in the beginning phase of the AscA and DesA segmentation. Therefore, lung segmentation is obtained and MR was separated with the lung region. Then AscA and DesA which are inside of MR are segmented make use of morphological properties

## II. MATERIALS AND METHODS

### A. Data Retrieval

In this study, data was collected from Dr. Siyami Ersek thoracic and cardiovascular surgery training and research hospital. All pulmonary computed tomographic angiography exams performed with 16 detectors CT (Somatom Sensation 16, Siemens, AG, Erlanger, Germany) equipment.

Patients were informed about the examination and also for breath holding. Imaging performed with Bolus tracking program. After scenogram, single slice is taken at the level of pulmonary truncus. A bolus tracking is placed at pulmonary truncus and trigger is adjusted to 100 HU (Hounsfield Unit). 70ml nonionic contrast agent at the rate of 4mL/sec with an automated syringe (Optistat Contrast Delivery System, Liebel-Flarsheim, USA) is used. When opacification is reached at the pre-adjusted level exam performed from the supraclavicular region to the diaphragms. Contrast injection performed via 18-20G intra venous cannula that was placed at antecubital vein. Scanning parameters were 120 kV, 80-120 mA, slice thickness 1 mm, pitch 1.0-1.2. Images reconstructed with 1mm and 5mm thickness, and evaluated at mediastinal window (WW 300, WL 50) with advanced workstation (Wizard, Siemens, AG, Erlanger, Germany) in coronal sagittal and axial planes. Oblique plans used if needed. Each exam consists of 400-500 images with 512x512 resolutions.

### B. Method

To segment AscA and DesA, firstly, lung segmentation is carried out. Then region which is between the left lung and the right lung is achieved as Mediastinum Region (MR). After these processes, images are threshold and components which are outside of the MR are removed. Then AscA and DesA are detected in the first image, which truncus rise, as 2D. Lastly, AscA and DesA are detected in the next images too. Therefore, 3D AscA and DesA are segmented from the 2D images. The detailed follow chart of this method is shown in Fig. 1.

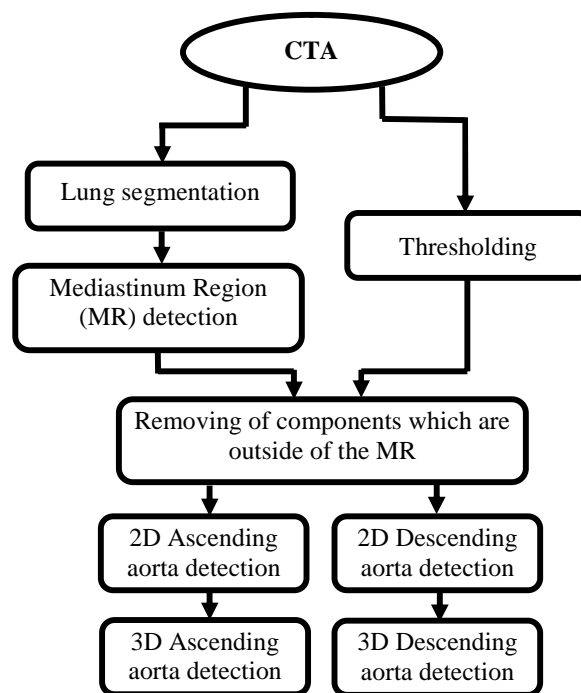


Fig. 1 The diagram of AscA and DesA segmentation method

CTA images, which are in hands, are 300 as being 2D. Firstly, to segment lung, each image has been threshold using images  $> -200$  HU as the level of threshold. Each of components in the image has been labeled with “Connected Component Labeling algorithm” (CCL) as 2D and ones whose number of voxels are under 500 were removed from the image. Lastly, regions, outside of patient’s body were removed and regions, inside of patient’s body were determined as right and left lungs [16]. After lung segmentation, MR was determined. For this, in each slice, minimum and maximum points of lung region were detected and, Xmin, Xmax, Ymin, and Ymax values were integrated. These values indicate the corner of the rectangle border (Fig 2b). Mediastinum region was determined as a rectangle which was reduced 20 voxels inward from each side of the rectangle border of lung region (Fig 2c).




Fig. 2 a) Original image, b) Left- right lung which detected corner c) Mediastinum Region

After these processes, each image has been threshold using  $150 \text{ HU} < \text{Image} < 500 \text{ HU}$  as the level of threshold (Fig 3).

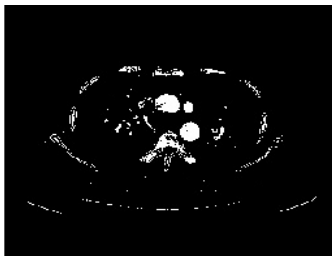


Fig. 3 Threshold image

Then, components which are outside of the MR were removed from the 2D images and the small gaps on the components were filled by gap filling filters. The small objects in lung region are problem. To remove the small objects, each component in the image has been labeled with CCL as 2D and ones whose number of voxels is under 250 were removed from the image (Fig. 4). These processes have been applied to all of the images from the image beginning of truncus to the image end of pulmonary vein.




Fig. 4 1- AscA 2- DesA

In Figure 4, the component, shown with number 1, is AscA. The component, shown with number 2 is DesA. This image is the first image which is processed and which truncus rises. AscA is the component at the top of the image, DesA is the component which is the nearest to right side of the image in first image which truncus rise belongs to the all patients.

To segment AscA and DesA, firstly Xmin and Ymax points are determined in Fig.4. Then, components in the image have been labeled with CCL as 2D and the labels which have Xmin and Ymax points are detected. Component which has label in Xmin point is detected as 2D AscA. Others are removed (Fig. 5a). Component which has label in Ymax point is detected as 2D DesA. Others are removed (Fig. 5b).



Fig. 5 a) AscA b) DesA

After the process which is applied in first image, AscA and DesA were detected in next images. For this process, image in Fig. 5a is gathered with the next one of 2D image for AscA (Fig. 6a) and image in Fig. 5b is gathered with the next one of 2D image for DesA (Fig. 6b).




Fig. 6 a) Gathered image for AscA b) Gathered image for DesA

AscA which carried out at the end of gathering is seen in white color because of its value of 2 and other components are seen in grey color because of their value of 1 (Fig. 6a). In the same way, DesA which carried out at the end of gathering is seen in white color because of its value of 2 and other components are seen in grey color because of their value of 1 (Fig. 6b). Components which have value of 1 are removed from both of the images. Thence AscA and DesA are detected in the all images as 2D. All of the 2D images are formed 3D AscA and DesA images.

### III. CONCLUSION AND DISCUSSION

The method, which has been tried at this work, applied to 30 different patients. Because of the fact that the segmentation in all CTA images (approximately 300) belonging to one

patient is solved in a short time as 1-2 minutes, it has a fast working property. It has been seen that the results at the end of applied method adjust to AscA and DesA determined with hand by the radiologists. With the help of this work, which performs AscA and DesA in a fast way, detection of aortic plaques, aneurysms, calcification, or stenosis can be done in a faster way.

#### ACKNOWLEDGMENT

The author would like to thank Assoc. Prof. Dr. Onur Osman and Assoc. Prof. Dr. Sinan Şahin. Besides, this work has been supported by Dr. Siyami Ersek Thoracic and Cardiovascular Surgery Training and Research Hospital, Istanbul, Turkey. The author wish to thank chief of staff in the hospital, Prof. Dr. Ibrahim Yekeler.

#### REFERENCES

- [1] Verdonck, B., Bloch, I., Maître, H., et al: Accurate segmentation of blood vessels from 3D medical images. In: IEEE Int Conf on Image Process. (1996) 311–314
- [2] Wink, O., Niessen, W.J., Viergever, M.A.: Fast delineation and visualization of vessels in 3-D angiographic images. IEEE Trans Med Imaging 19 (2000) 337–346
- [3] Osher, S.J. and Sethian, J.A. Fronts propagating with curvature dependent speed. J. Comput. Pysc, vol.79, pp. (1988)12-49.
- [4] Kass, M., Witkin, A., Terzopoulos, D., Snakes: active contour models, International Journal of Computer Vision 1 (1988) 321–331.
- [5] Li, C., Kao, C., Gore, J., Ding, Z., Minimization of region-scalable fitting energy for image segmentation, IEEE Transactions on Image Processing 17 (2008) 1940–1949.
- [6] Katz, W.T., Merickel, M.B.: Aorta detection in magnetic resonance images using multiple artificial neural networks. In: Annual Int Conf of the IEEE Eng Med Biol Mag. (1990) 1302–1303
- [7] Tek, H., Akova, F., Ayvaci, A.: Region competition via local watershed operators. In: IEEE Comput Soc Conf on Comput Vis and Pattern Recog. (2005) 361–368
- [8] Pohle, R., Toennies, K.D.: Segmentation of medical images using adaptive region growing. In: SPIE Med Imaging Conf. (2001), volume 4322.
- [9] Boskamp T, Rinck D, Link F, et al. New Vessel Analysis Tool for Morphometric Quantification and Visualization of Vessels in CT and MR Imaging Data Sets, Radiographics, (2004);24(1):287-297.
- [10] Li, C.M., Xu, C.Y., Gui, C.F., Fox, M.D., Level set evolution without reinitialization: a new variational formulation, in: IEEE Conference on Computer Vision and Pattern Recognition, San Diego, 2005, pp. 430-436.
- [11] Lie, J., Lysaker, M., Tai, X.C., A binary level set model and some application to Mumford–Shah image segmentation, IEEE Transaction on Image Processing 15(2006)1171–1181.
- [12] Lončarić, S., Subasić, M., Soratin, E.: 3-D deformable model for abdominal aortic aneurysm segmentation from CT images. First Int Workshop on Image and Signal Process and Anal (2000)
- [13] Lorenz C, Renisch S, Schlathöller T, et al. Simultaneous segmentation and tree reconstruction of the coronary arteries in MSCT images. vol. 5031. SPIE; (2003) p. 167ü177.
- [14] Wörz S, Rohr K. Segmentation and Quantification of Human Vessels Using a 3-D Cylindrical Intensity Model. IEEE Trans Image Process. (2007);16(8):1994-2004.
- [15] Kovacs T, Cattin P, Alkadhi H, et al. Automatic Segmentation of the Vessel Lumen from 3D CTA Images of Aortic Dissection. Procs BVM. (2006), p. 161-165.
- [16] Özkan H., Osman O., Şahin S., Atasoy M. M., Barutca H., Boz A.F., Olsun A., “Lung Segmentation Algorithm for CAD System in CTA Images” World Academy of science Engineering end Technology (ICBCBBE 2011), July 24- 26, 2011, Paris